Fibro-osseous lesions

LAB.6

DR.NOOR

Fibrous dysplasia is a developmental tumor like condition that is **characterized by** *replacement of normal bone by an excessive proliferation of cellular fibrous connective tissue intermixed with irregular bony trabeculae.*

Radiographic

-Ranges from a radiolucent lesion to a uniformly radiopaque mass.

-Classical presentation is ***ground-glass*** effect.

- Results from the superimposition of poorly calcified bone trabeculae arranged in a disorganized pattern.

-The margins blend into the adjacent normal bone so that the limits of the lesion may be difficult to define.

IM:27000
: 188.1
DFOV:235.29
ALG:
R
I
L
S
kV:120.0
mA:120

Fibrous dysplasia. Periapical radiograph showing a diffuse “ground-glass” radiographic appearance.

Fibrous dysplasia

Monostotic form more common in the craniofacial region

Ground glass change with areas of sclerosis (arrows)

More ill-defined border compared to ossifying fibroma

Fibrous dysplasia:

"orange peel"appearance of fine dense trabeculae seen on intra-oral radiography in late stage.

Fibrous dysplasia: Note orange peel appearance of trabeculations on intraoral radiography (Case courtesy of Dr. Robert P. Langlais)

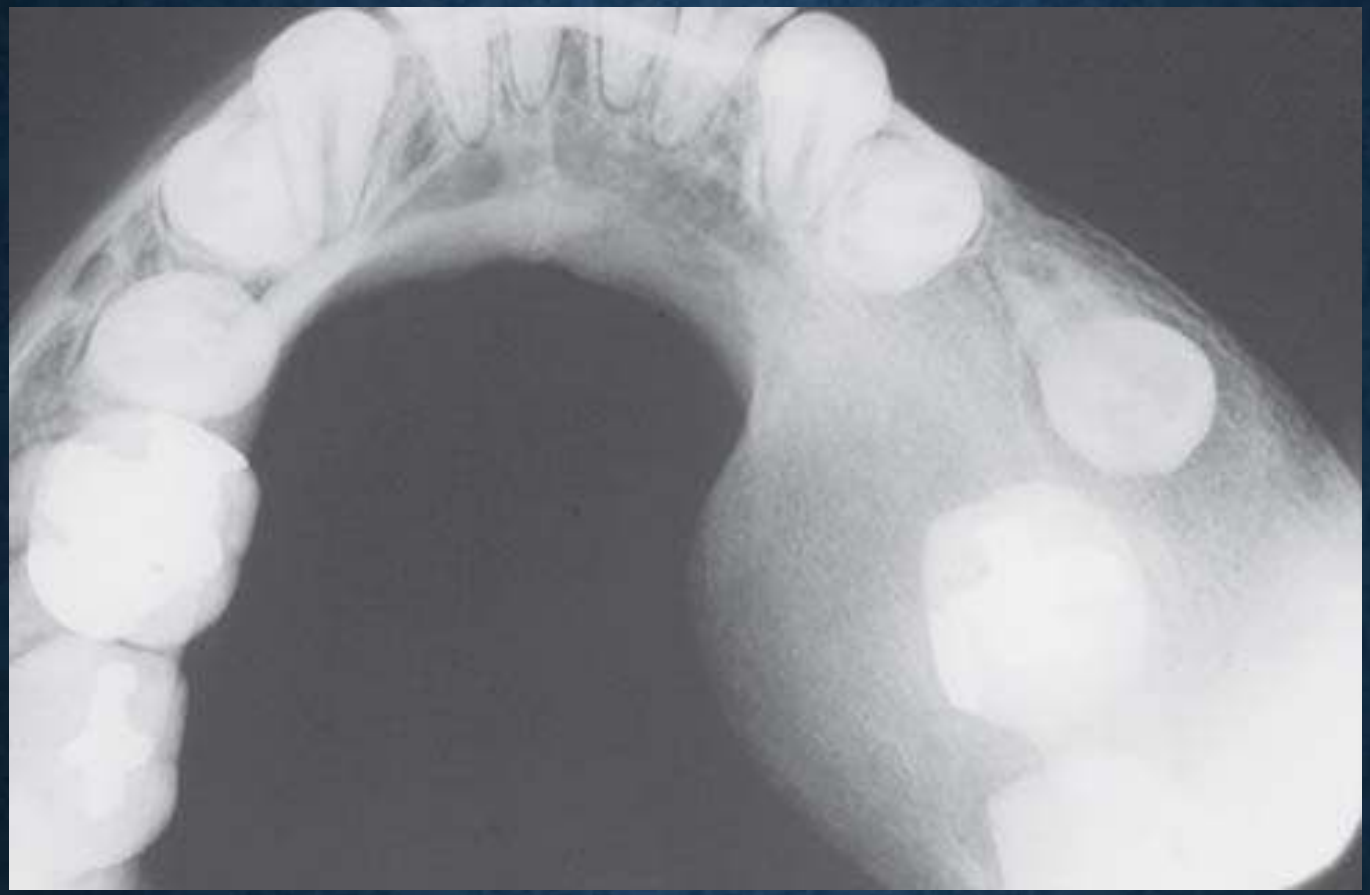

Fibrous dysplasia.
Occlusal radiograph showing localized expansion of the mandible and the "ground-glass" radiographic appearance. The margins of the lesion are not defined and blend into the adjacent bone

The histologic appearance of FD

usually exhibits a moderately cellular, fibrous stroma containing irregularly shaped trabeculae of immature bone.

The trabeculae tend to be delicate and have been linked to ***Chinese characters-writing****, without osteoblastic rimming activity.*

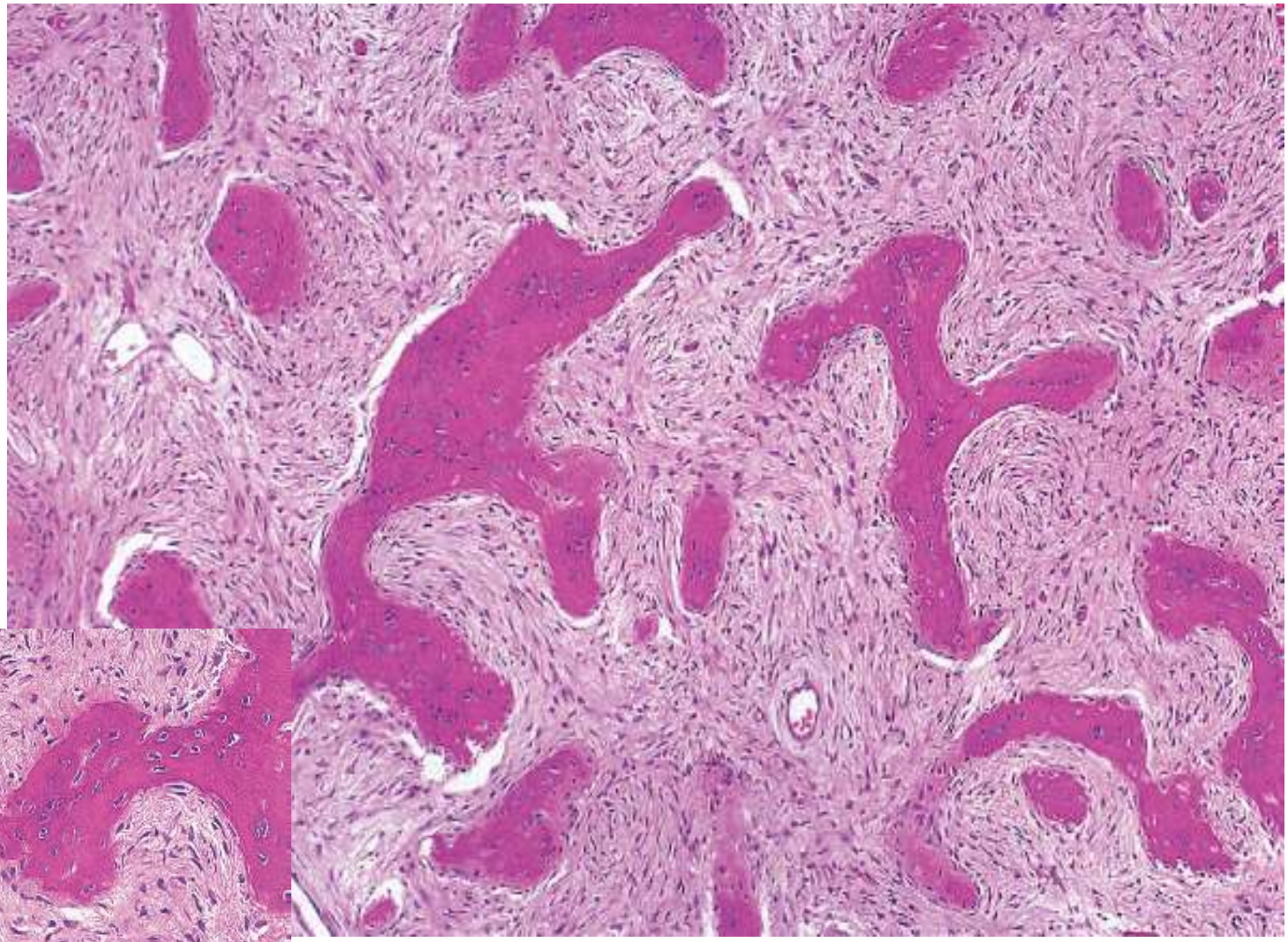

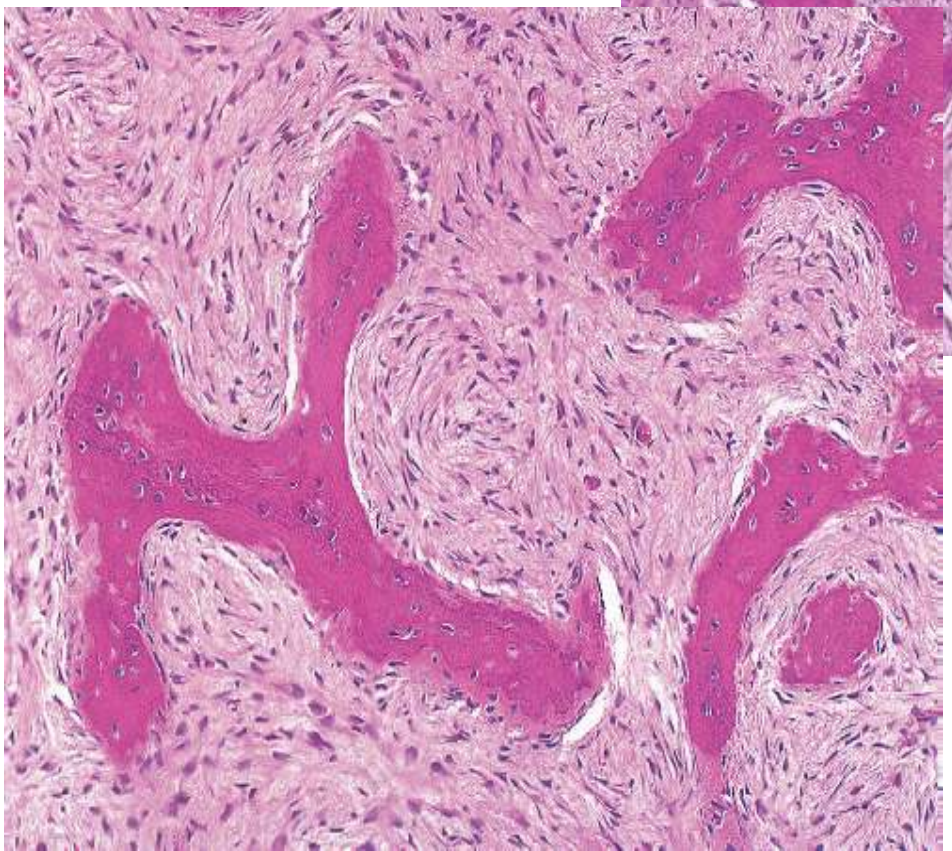

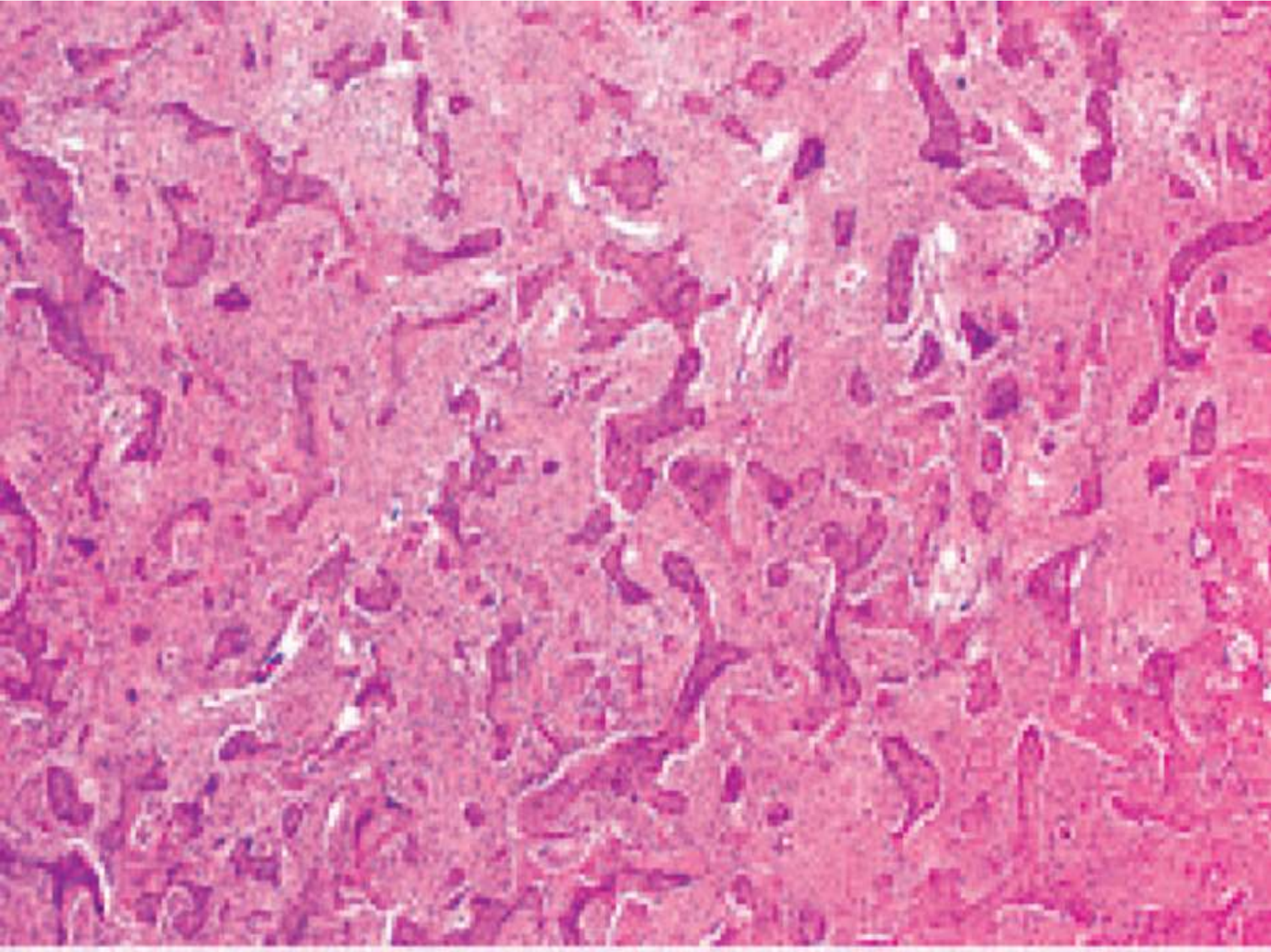

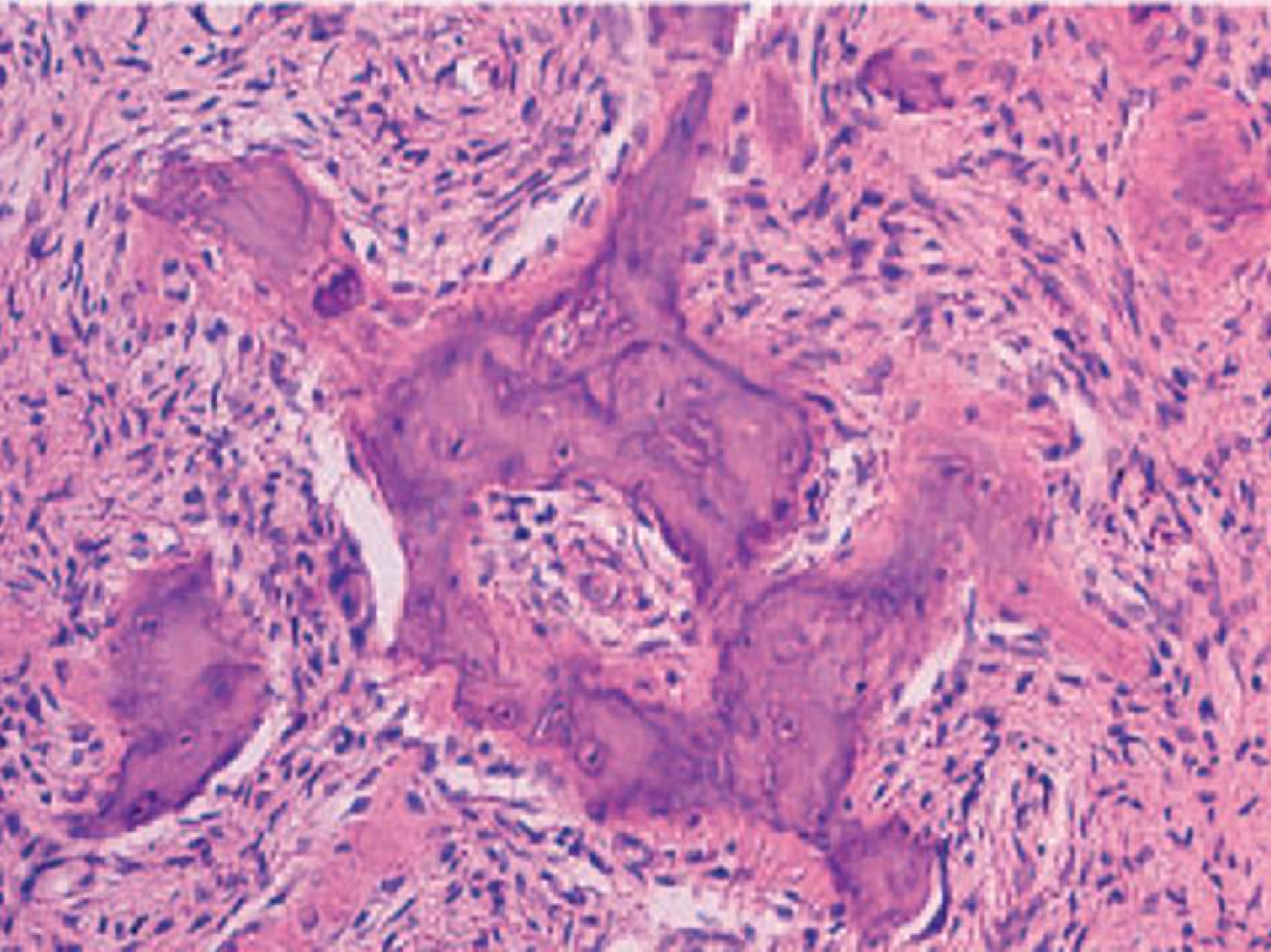

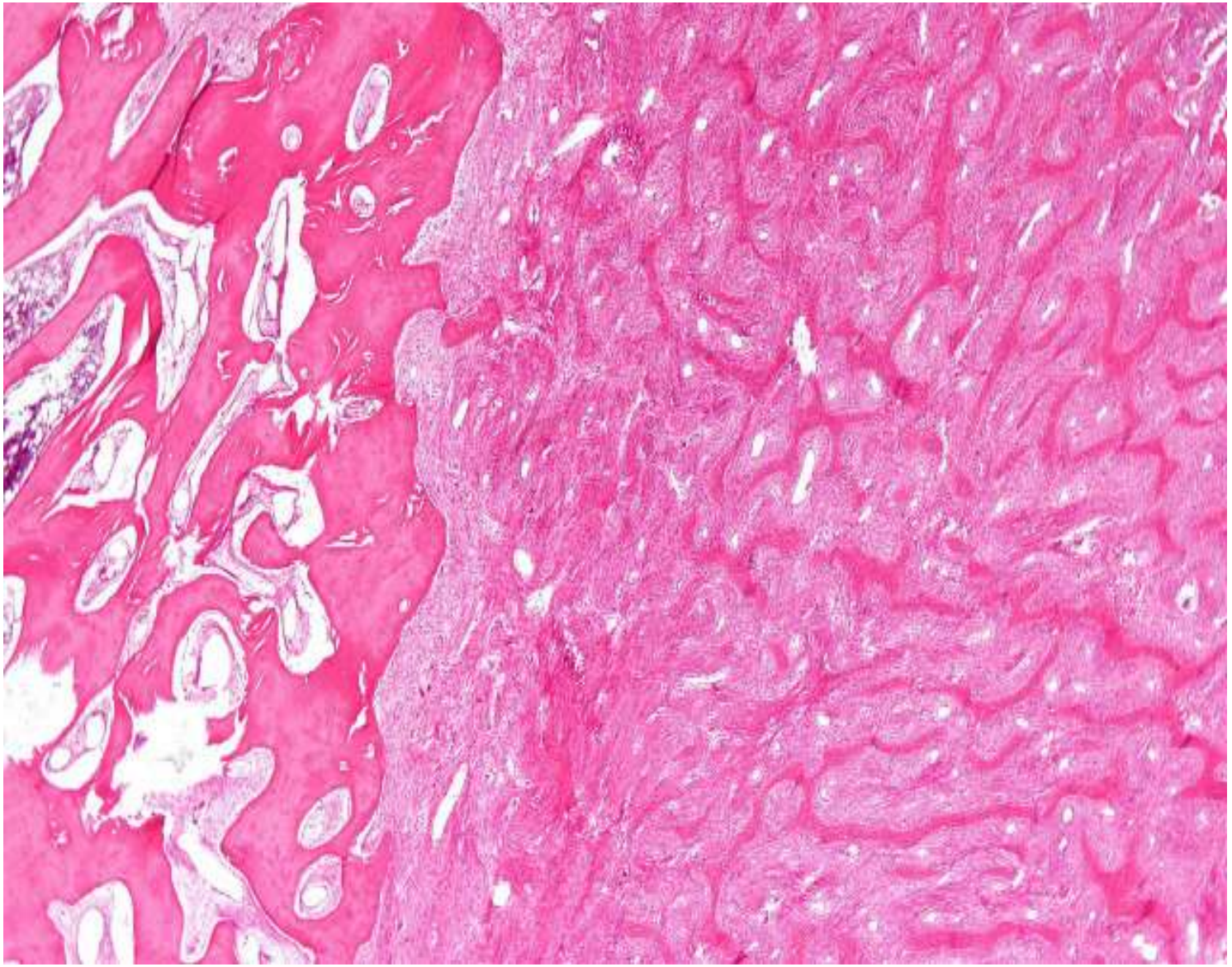

epresentative panoramic radiographs (a) and photomicrographs of H&E-stained (b, c) gnathic fibrous dysplasia. In panoramic radiographs, gnathic fibrous dysplasia is homogeneously radio-opaque with a ground-glass appearance and poorly defined margins indicated by the red arrow. The photomicrographs show that gnathic fibrous dysplasia shows thin irregular-shaped woven bone that resembles membranous ossification.

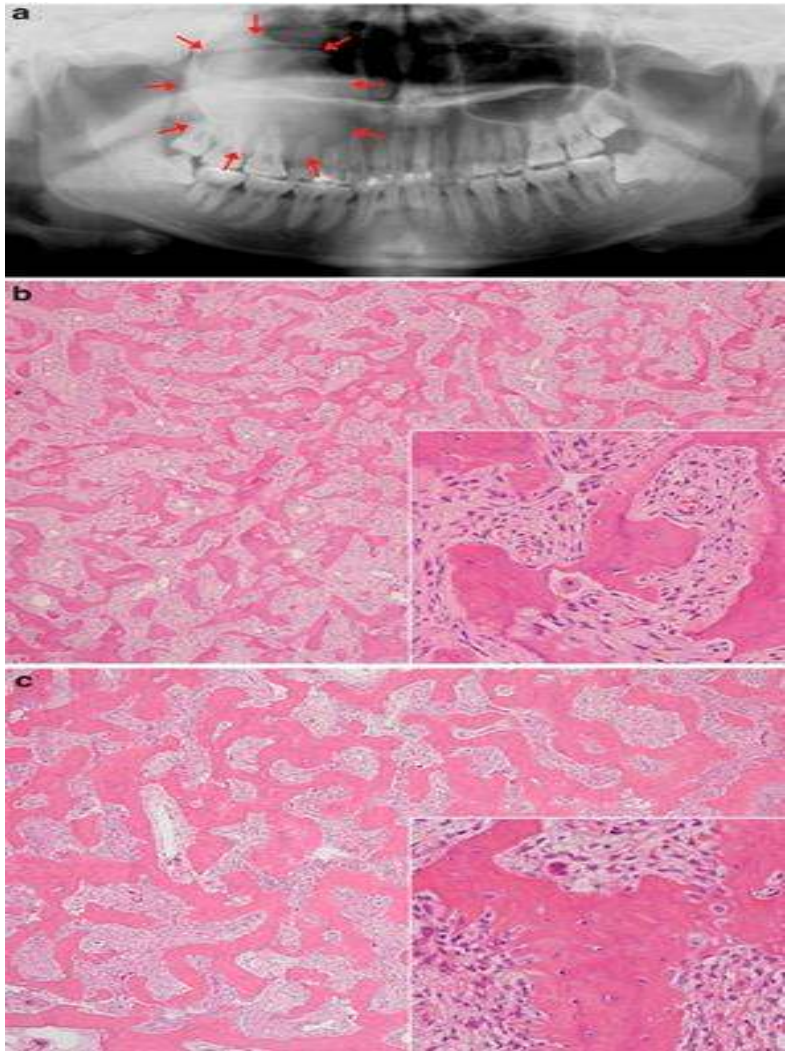

OSSIFYING FIBROMA (OF)

CEMENTO OSSIFYING FIBROMA (COF)

Radiographic Findings of OF:

Well circumscribed, sharply demarcated border is the most common presenting radiographic feature.

May present as relatively lucent or opaque depending on the density of the calcification present.

Also they may be unilocular or multilocular, mixed radiolucent-radiopaque image may be seen.

The roots of the teeth present may be displaced & less commonly resorption is seen.

expansile lytic lesion in the body of mandible involving the roots of premolars, first and second molars. The lateral aspect of the lesion shows faint radiopacity

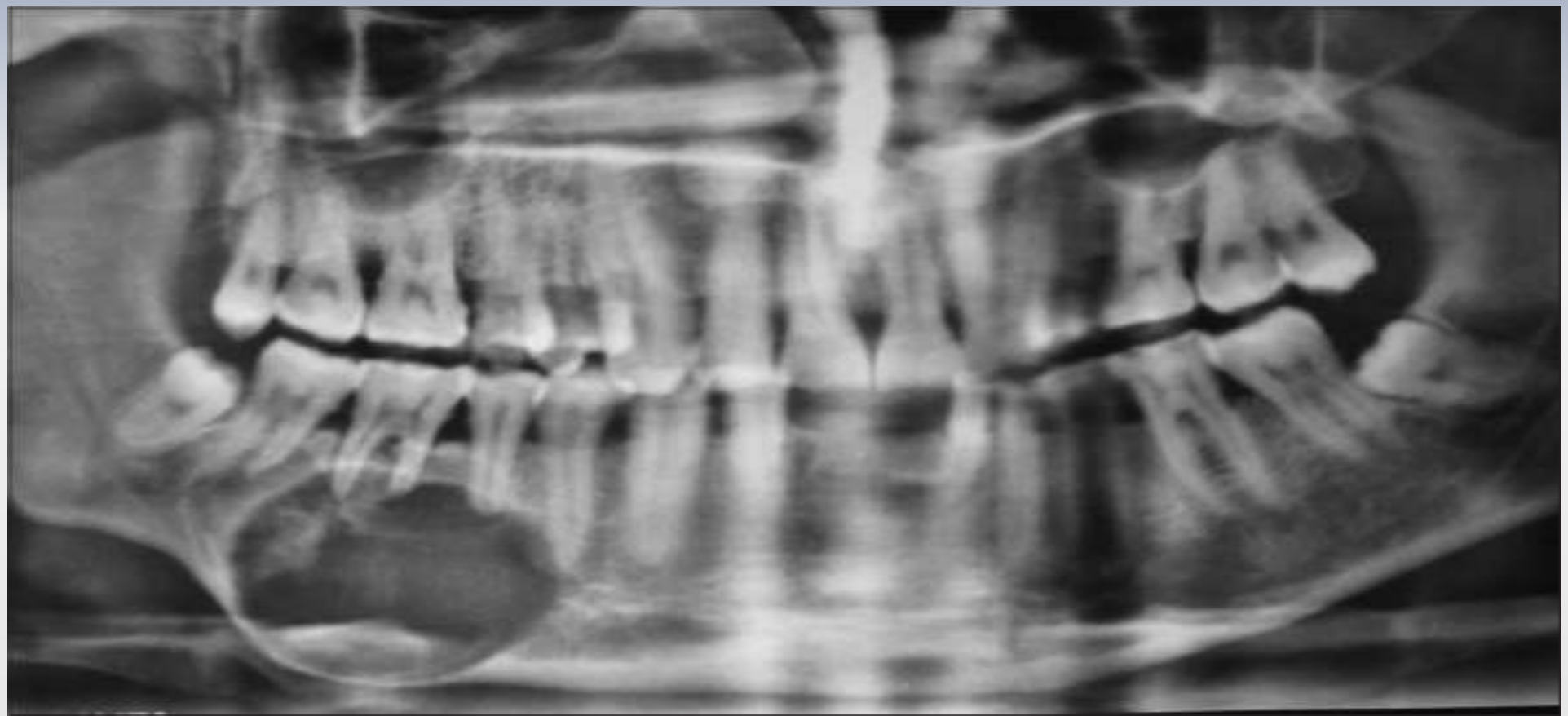

Computed tomography three-dimensional surface shaded display images from frontal (a) and basal (b) view showing the expansile lesion with smooth outlines without any cortical break

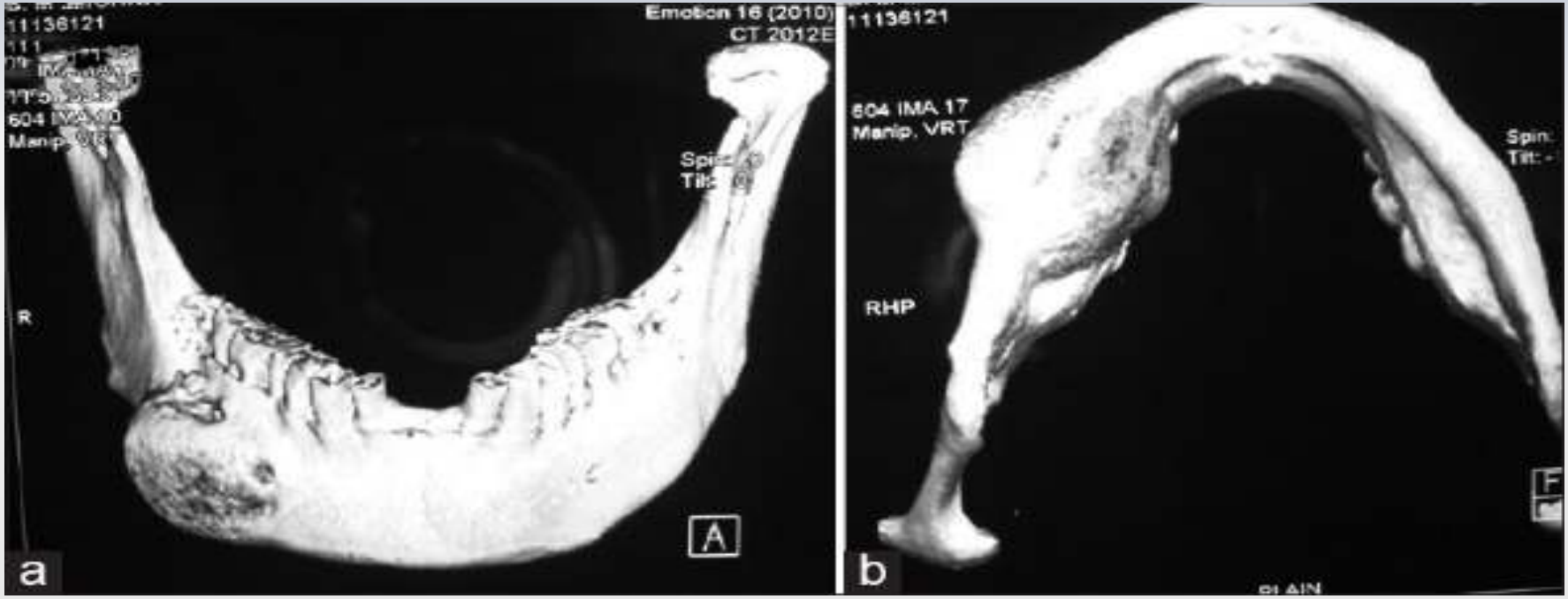

Well-delimited mixed radiographic image causing displacement of the involved teeth

mixed radiolucent and radiopaque lesion expanding the tooth

RIGHT
LEFT

expansion of both the cortical plates from canine area to anterior border of ramus of mandible of the left side

Histopathology of (OF):

*Is composed of **f brous connective tissue** with well-differentiated spindle fibroblasts.*

Bone trabeculae or islands are evenly distributed throughout the fibrous stroma.

*The bone is immature & often surrounded by osteoblast **(osteoblast rimming)**.*

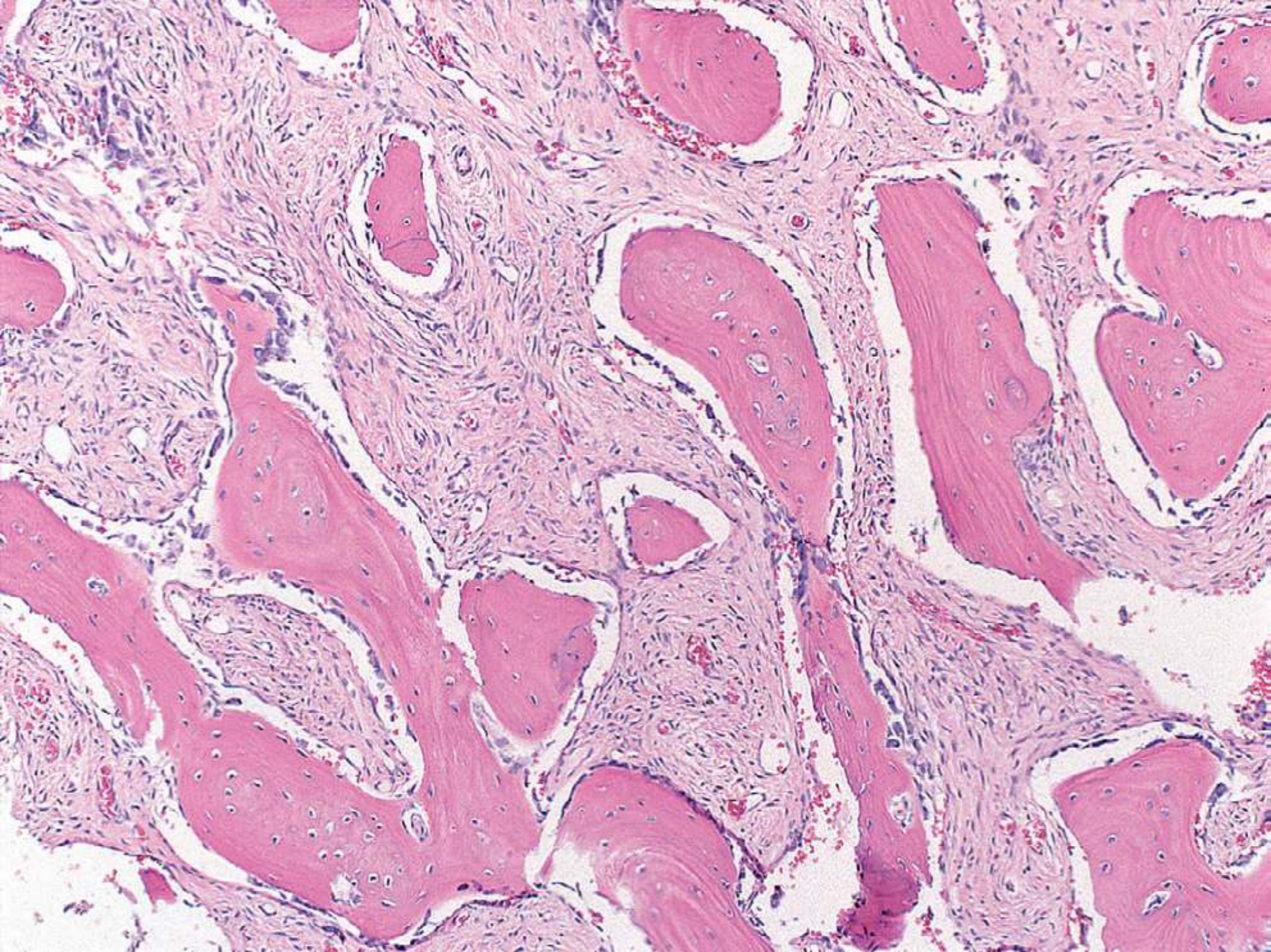

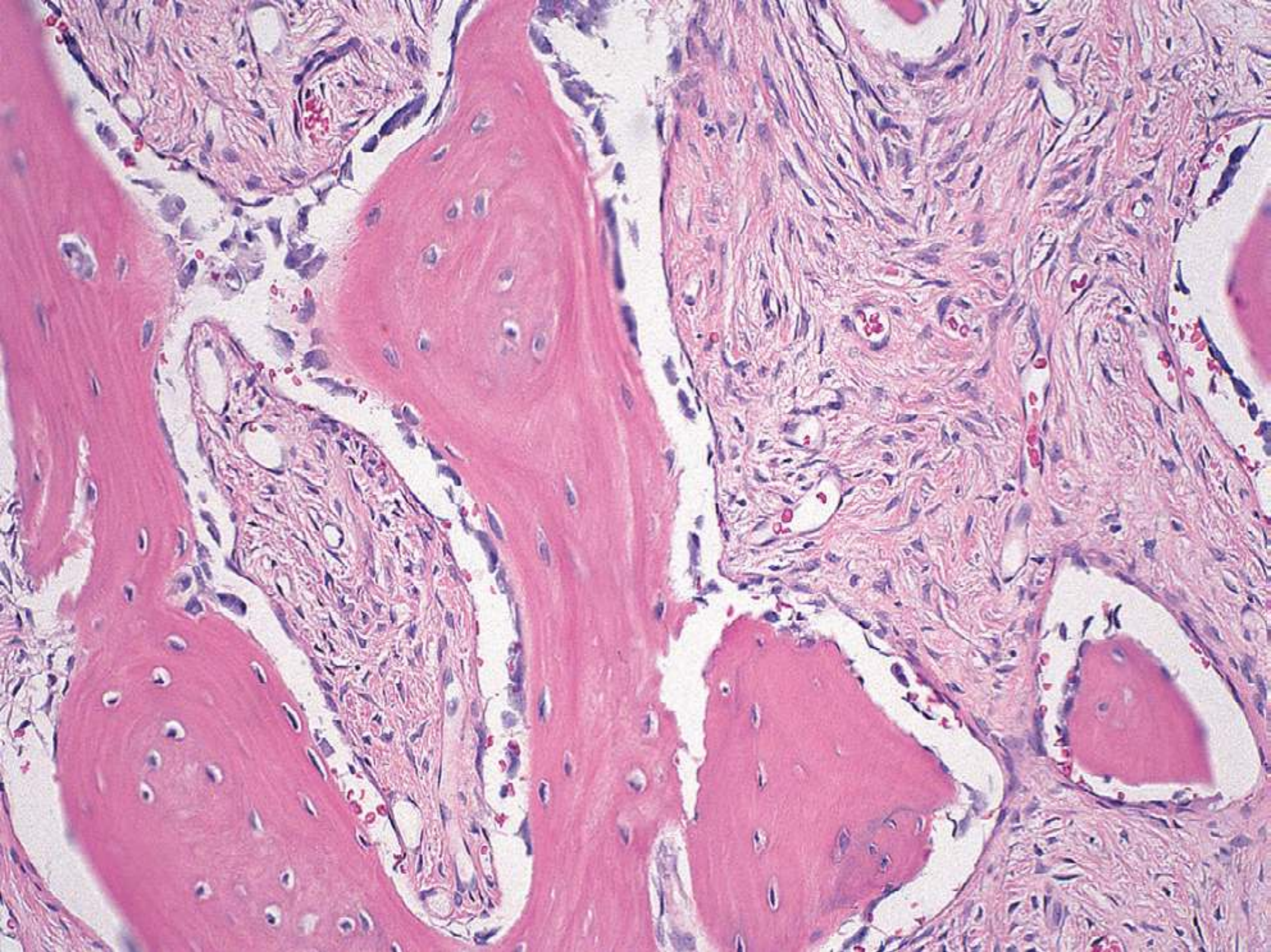

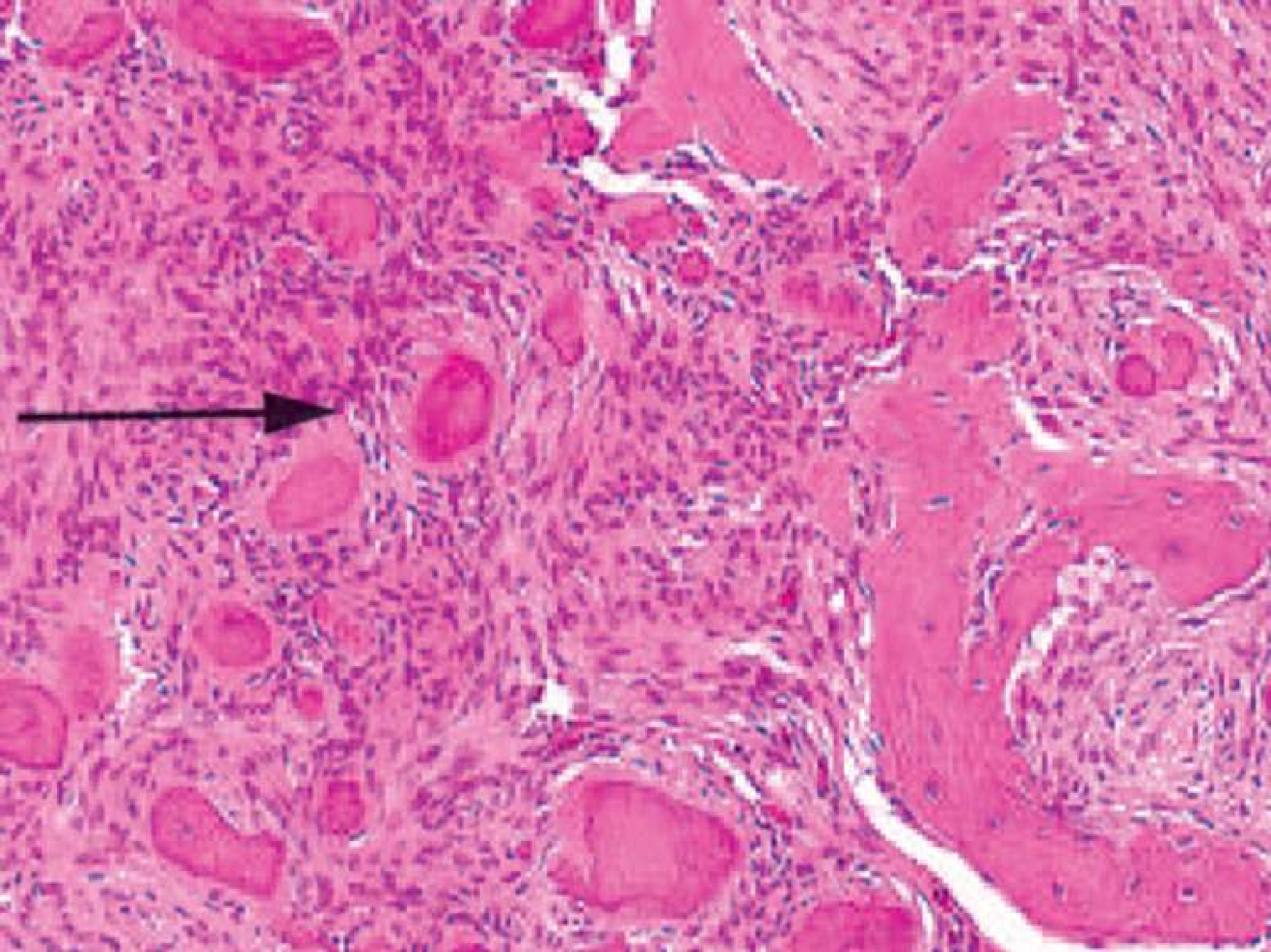

Central Ossifying Fibroma

Histopathology

- Islands and trabecular of immature bone
- Immature fibrous stroma
- Maybe: dark cementoid calcified globules

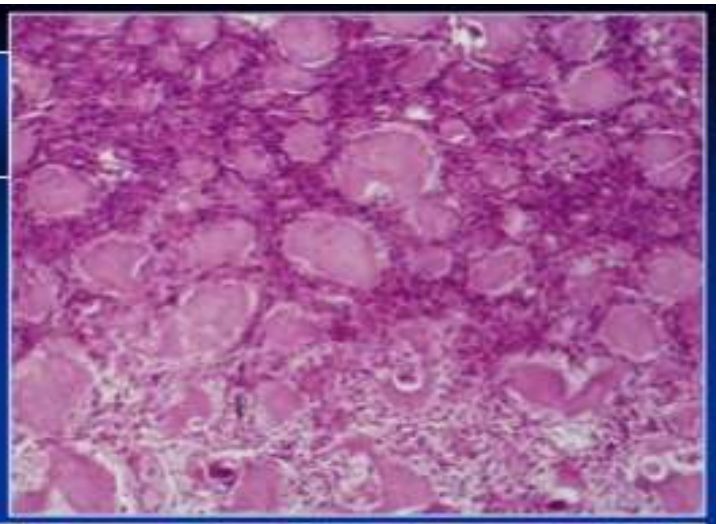

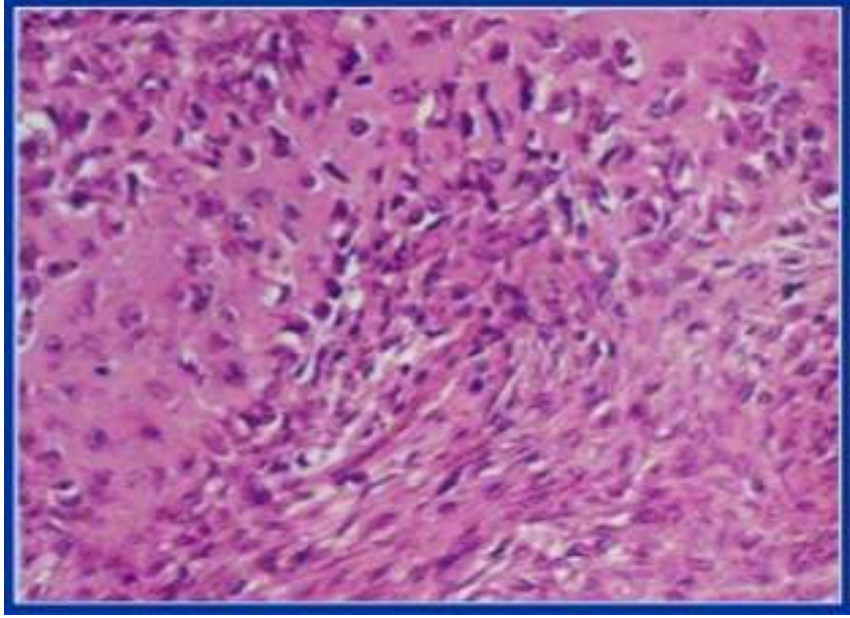

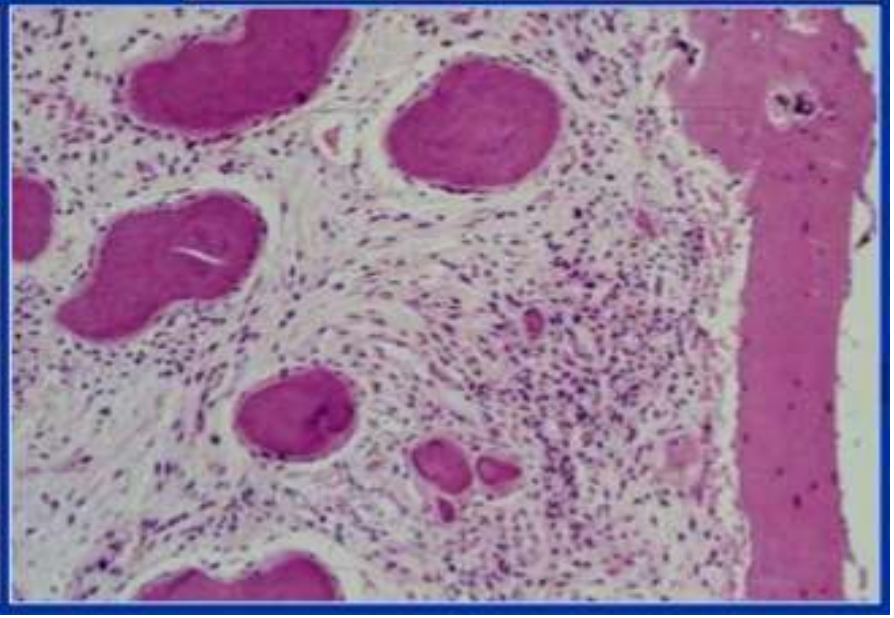

ossifying fibroma showing scattered osteoid mass in fibrous tissue

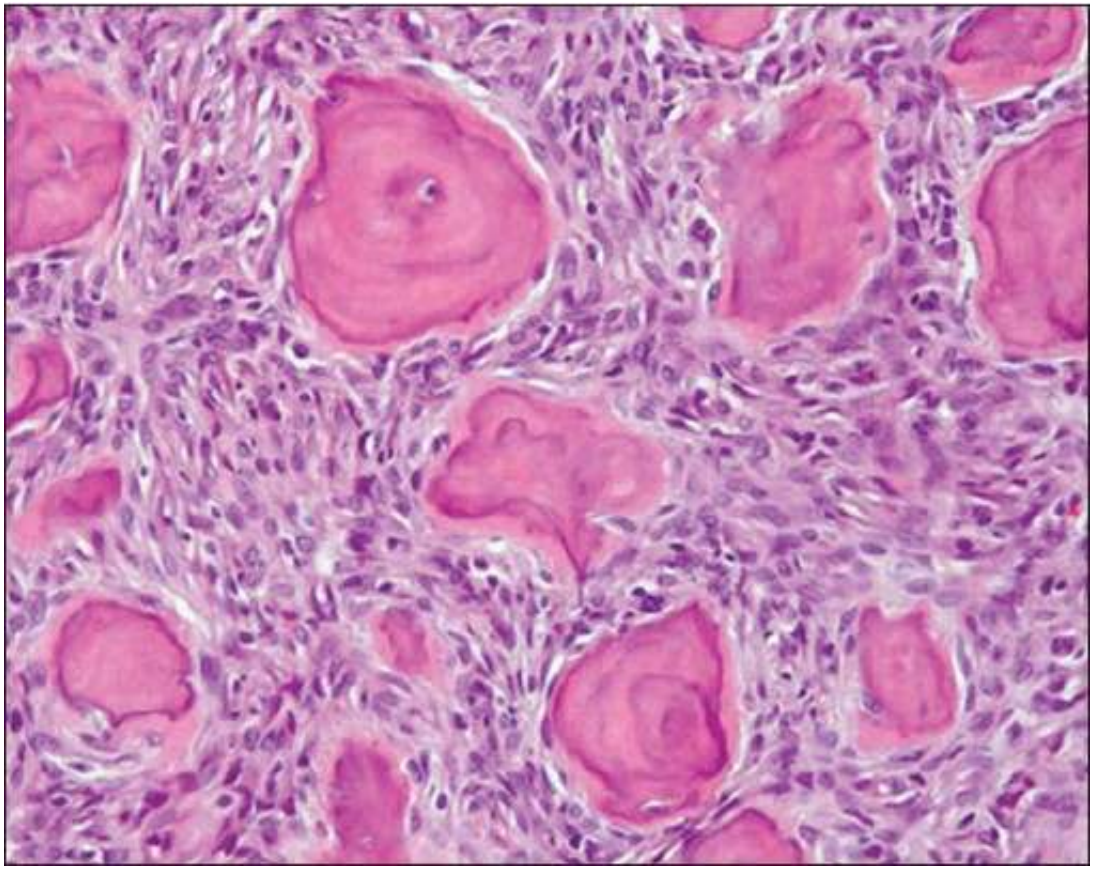

CEMENTO-OSSEOUS DYSPLASIA (COD)

Cemento-osseous dysplasia *is the most common f bro-osseous lesion occurring in the tooth bearing areas of the jaws. COD is a group of non neoplastic processes usually conf ned to the tooth bearing areas of the jaws or edentulous alveolar processes*

COD includes:

- ***Periapical COD.***
- ***Focal COD.***
- ***Florid COD.***

Radiology;

*Early lesions appear as circumscribed areas of **radiolucency** involving the apical area of a tooth. the lesions tend to "mature" over time to create **a mixed** radiolucent and radiopaque appearance*

In the end stage, the lesions show a circumscribed dense calcification surrounded by a narrow radiolucent rim.

Periapical cemento-osseous dysplasia. Later-stage lesions exhibiting significant mineralization.

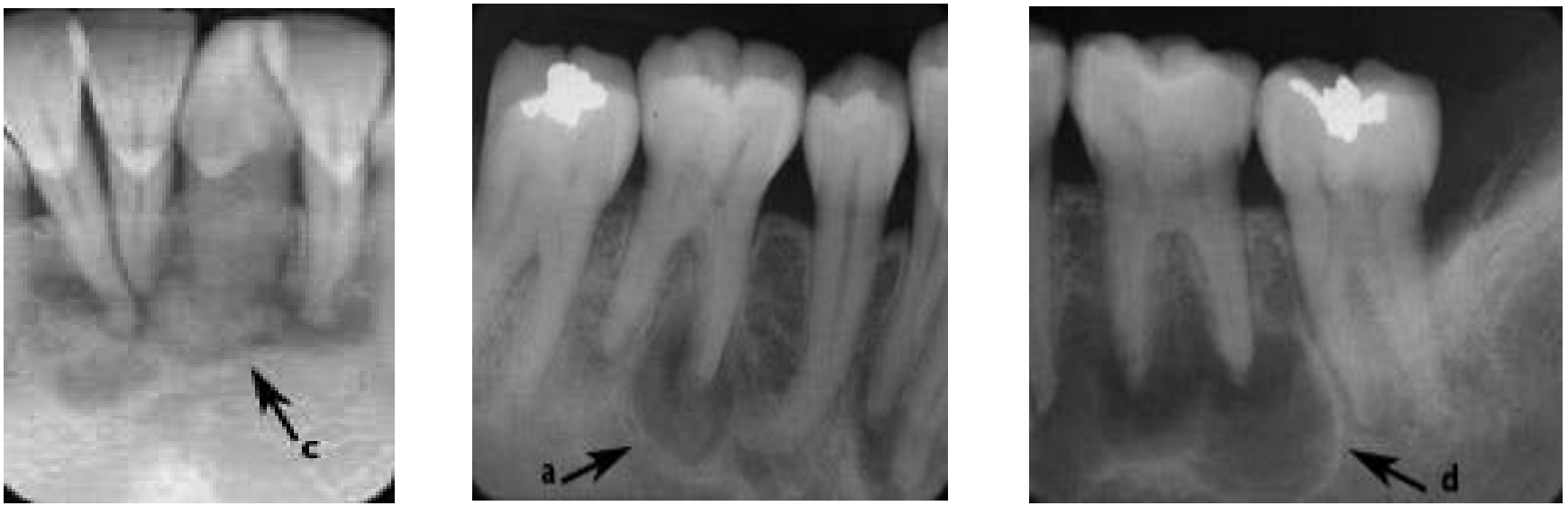

cemento-osseous dysplasia:
(**a** to **c**) mandibular teeth with primarily radiolucent periapical areas and others with cementum-like internal radiopacities surrounded by a radiolucent band (arrows); (**d**) a well-defined corticated simple bone cyst with evidence of inter-radicular scalloping (arrow).

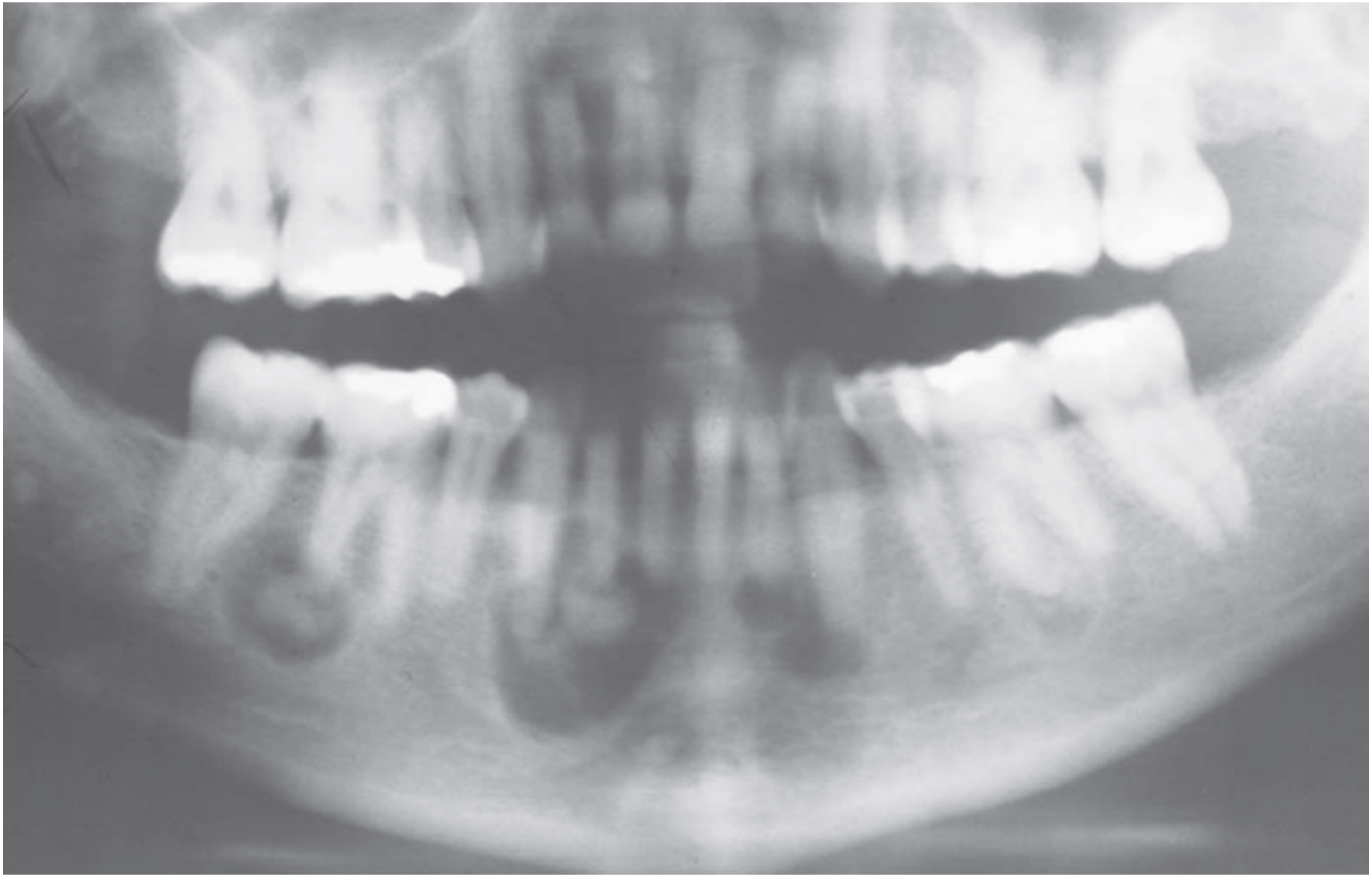

Florid cemento-osseous dysplasia. Multiple mixed radiolucent and radiopaque lesions involving the anterior and posterior regions of the mandible.

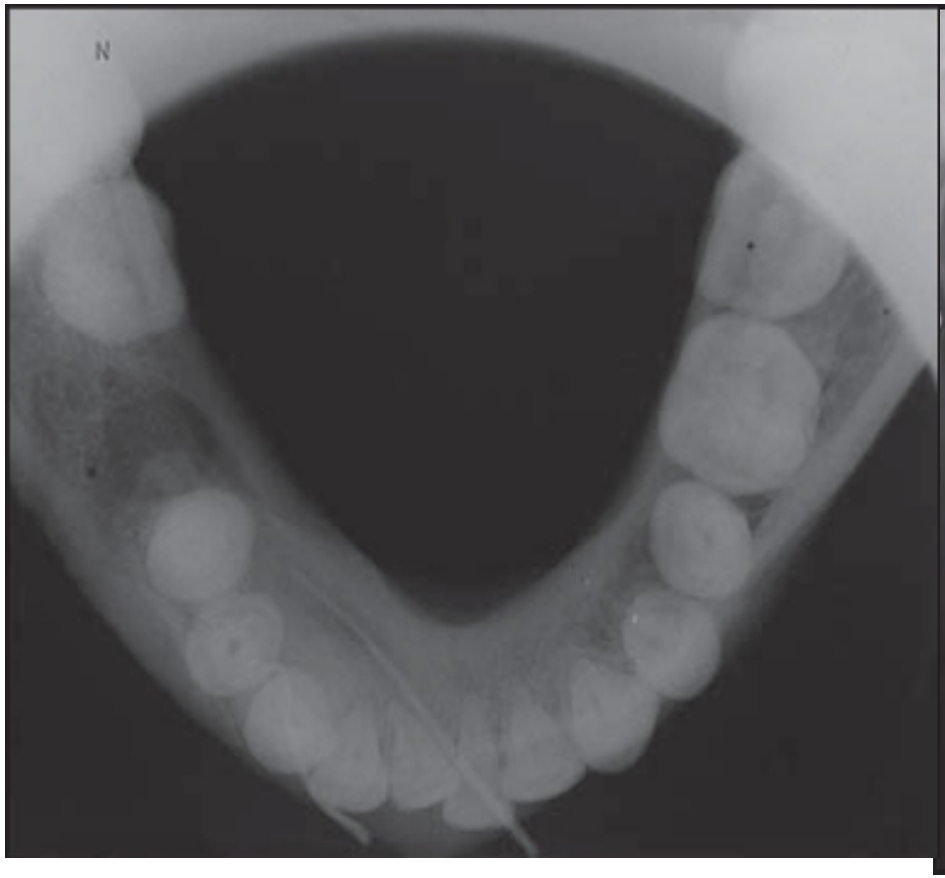
N

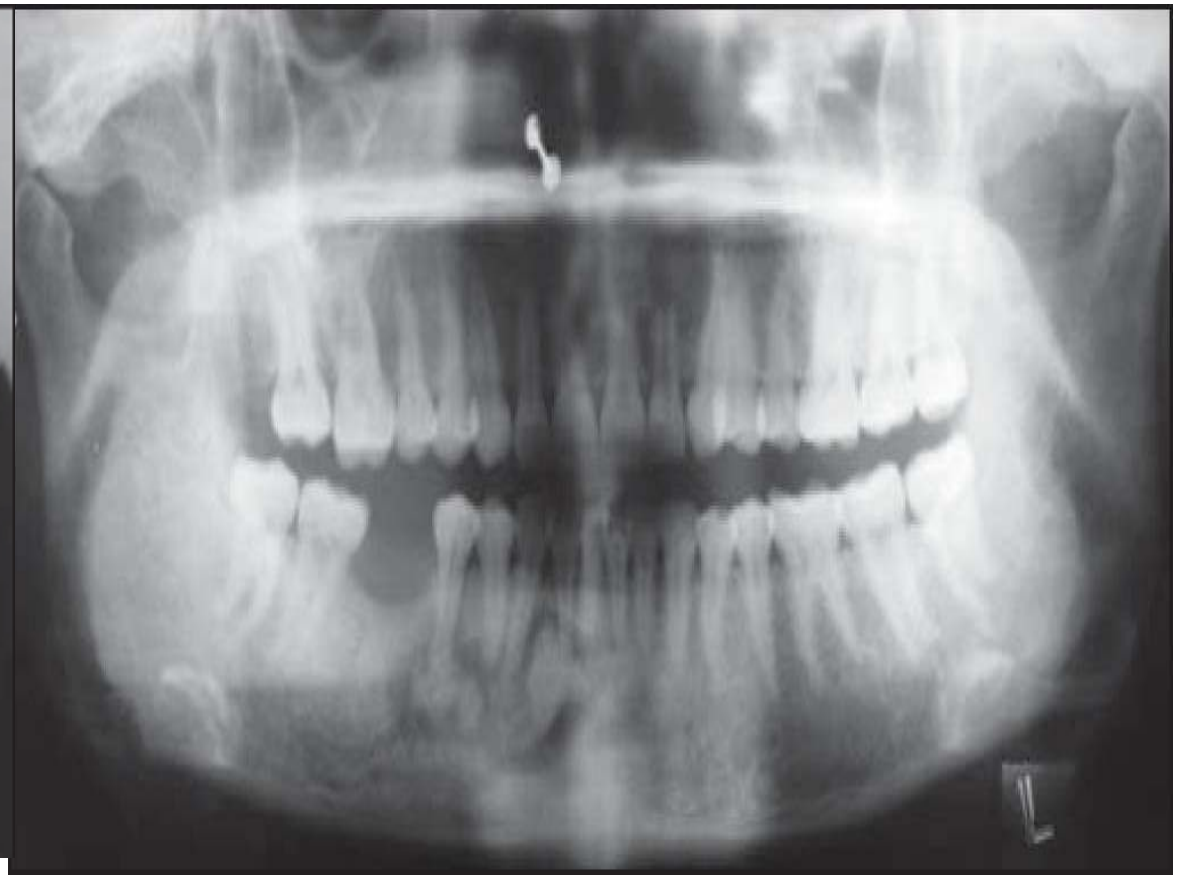
L

Histopathology:

The tissue consists of fragments of cellular mesenchymal tissue composed of spindle shaped fibroblasts and collagen fibers with numerous small blood vessels.

Free hemorrhage is typically noted interspersed throughout the lesion.

Within the this fibrous connective tissue background dense, sclerotic masses which have been interpreted as cementum is seen.

As the lesions mature and become more sclerotic, the ratio of fibrous connective tissue to mineralized material decreases.

Florid Cemento-Osseous Dysplasia. Yellowish, avascular cementum-like material is beginning to exfoliate through the oral mucosa.

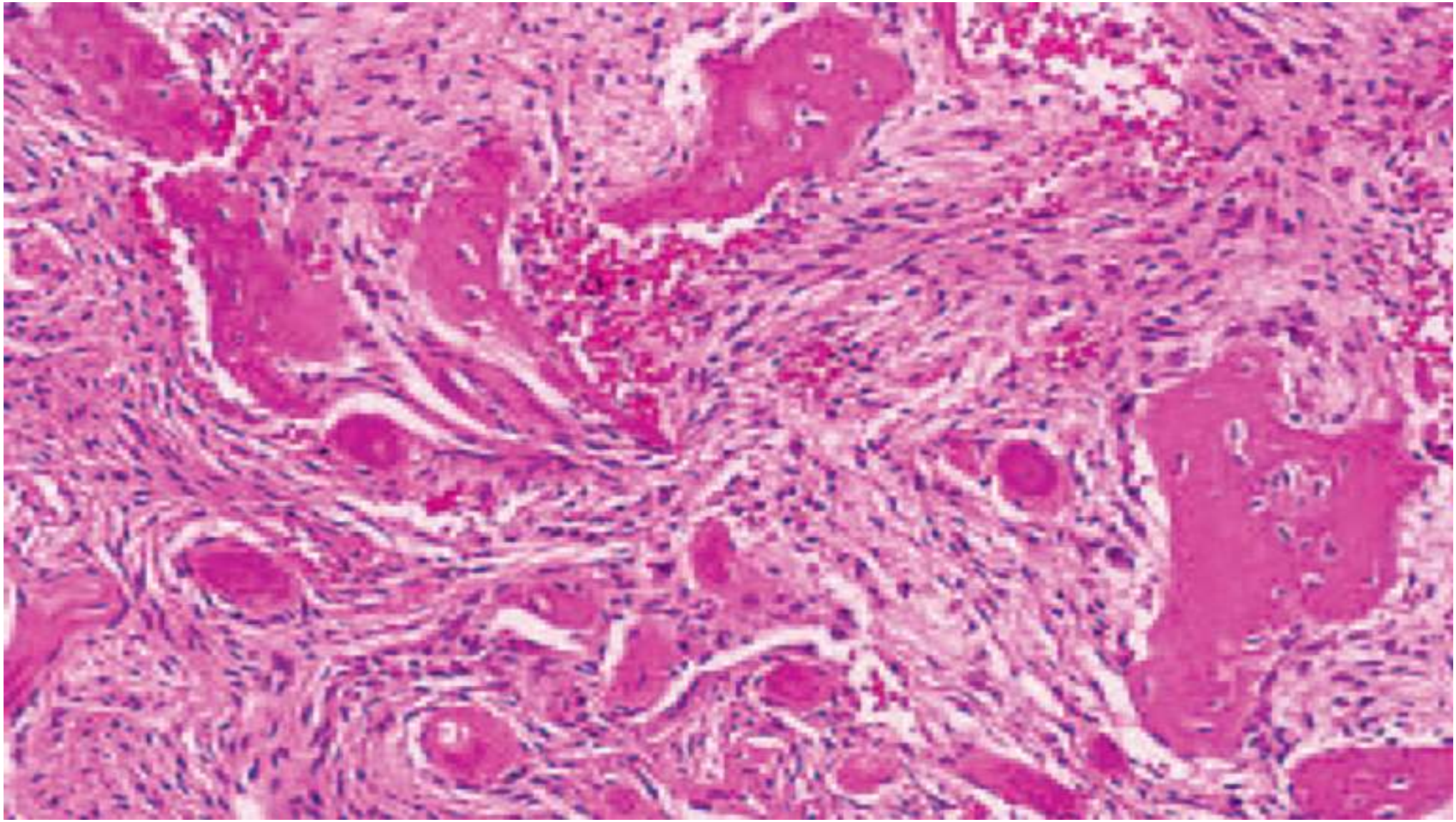

Cemento-osseous dysplasia. spicules of bone and cementum like hard tissue within moderately cellular fibrous connective tissue. Note the hemorrhage around the bony trabeculae.

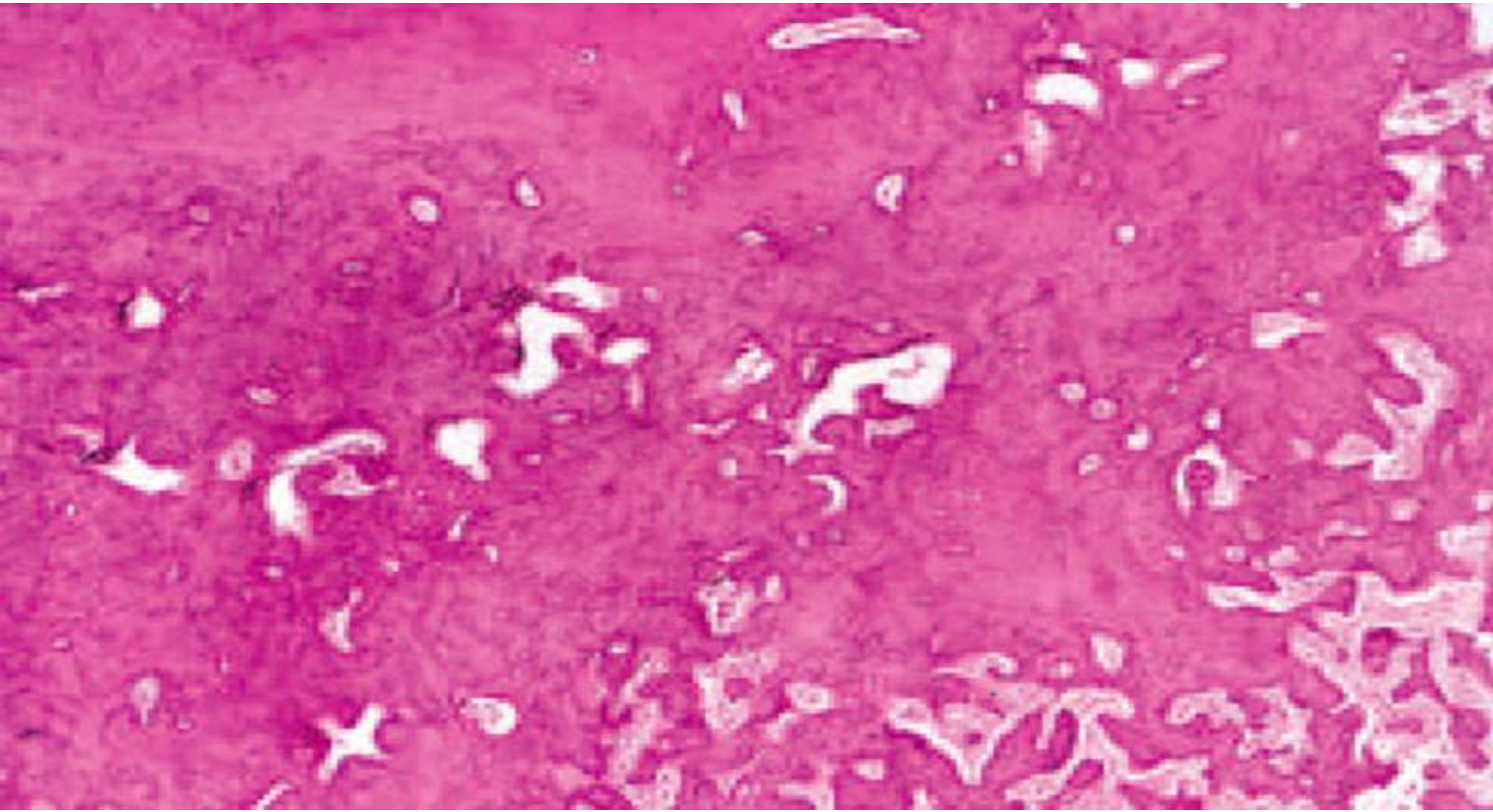
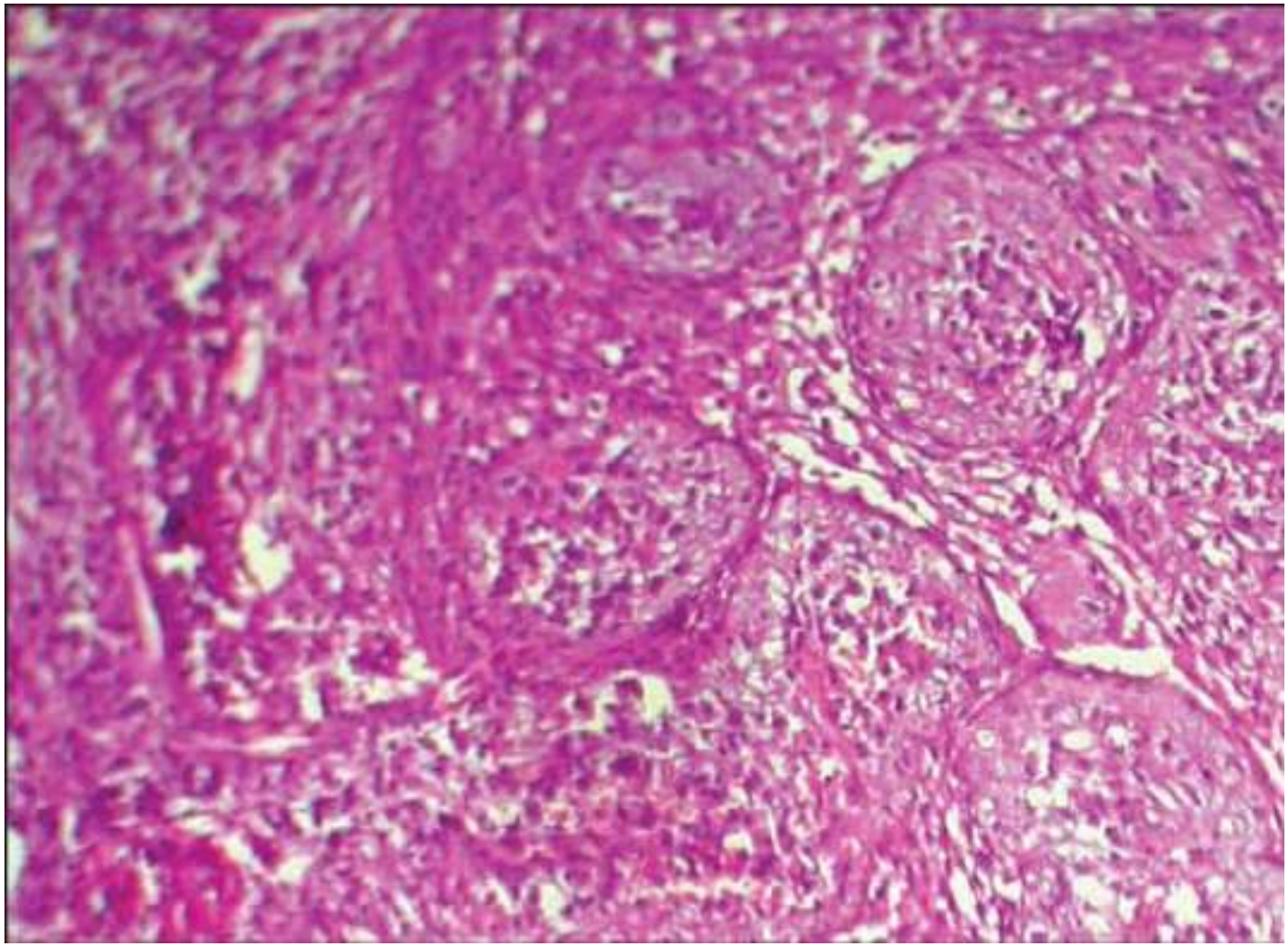
Cemento-osseous dysplasia. Late-stage lesion showing a sclerotic mass of Cemento-osseous material.